Adelaide Hills
EQUINE CLINIC

Dr Darren Arnold B.Sc, BVMS
Dr Fiona Jacob MA, Vet MB, MRCVS
Dr Daniel Sims BVSc (Hons)

Cnr Main Road/River Road Hahndorf PO Box 471 Hahndorf SA 5245
Ph 08 8388 7489 **Fax** 08 8188 1085 **email** clinic@hillsequine.com.au
24 hour emergency service available **web** www.hillsequine.com.au

3rd October 2013

Re Millie, 13yr QH X Mare owned by Chris Sanderson. Examined 3rd October 2013 at 889 Onkaparinga Valley Road, Oakbank.

The above mare was presented with concern regarding a right hindlimb issue in the hock area, and also behavioural problems since her purchase 3 months prior. At the time of examination the mare was not in work. A full clinical examination was carried out, alongside a trot up, flexion tests and examination of her gait on the lunge.

Significant Clinical Findings :

The Right Hock area was found to be thickened (especially on the inside aspect) down the area of the tarsal sheath, deep digital flexor tendon and through the entirety of the Tarso-Crural Joint (The large top joint of the hock). The soft tissue thickening continued down to the level of the proximal cannon on the inside of the limb, and was non – painful to palpate. The mare resented hard upper limb flexion. The rest of the right hindlimb was within normal limits. Both hind fetlocks and distal tendon sheaths carried some fluid, but both were non painful on palpation of the soft tissues and hard distal limb flexion.

Millie was very mildly lame (1/10) right hind on trot up. Flexion tests of both forelimbs and the left hind were normal, but the right hind flexion test was positive. On the lunge there was a marked lameness of the right hind on the L rein (3-4/10) and also a 3/10 right hind lameness on the right rein.

It was decided to X-Ray the right hind hock area (with comparative views of the left hock area) since there was clinical evidence of bone change as well as soft tissue change. X-rays showed calcification of the soft tissues in the region of the tarsal sheath, as well as some roughened and chipped bone at the back of the joint (See below). Overall, the bone through this right hock area appears 'moth eaten' in nature which I feel is a result of chronic inflammation in this area. This bone is likely to be weakened and so there is a chance of repeat areas of bone breaking off and even a catastrophic fracture.

I have had Dr Darren Arnold assess these images with me, to provide a surgical perspective. It is our feeling that surgical intervention is not going to be beneficial in Millie's case. The bone chips that we can see on the x-rays are likely to be embedded within cartilage and not accessible to remove. In addition, removing the bone chips is not going to alter or improve the soft tissue damage surrounding the hock, or reverse the weakened arthritic bone which exists already.

We would propose the following treatment options to move forward with Millie:

1. Medication of the affected hock joint and probably the distended tendon sheath in this area (we may need to scan the hock area with an ultrasound scanner to assess if the tendon sheath needs medication also). The aim of this is that by directing targeted steroid anti-inflammatory treatment at the painful area we reduce the swelling and pain associated with the changes that exist. We cannot reverse the bony change but we can help alleviate the inflammation resulting from this. We could also inject a product (Hyonate) which would help with joint lubrication and cartilage health in the area of the joint. The approximate cost to scan is $132, and to medicate the areas would be in the region of $250-300. We could do the whole lot for $350 if you were interested in this. In terms of management after these injections Millie would have a bandage on for 2-3 days but be ok in the paddock. Then a week off work before starting some lunge-ing work with the aim to get her back into regular work if she looks good. There is no guarantee of how she will respond, or how long for, but this medication option would be the most likely to produce some results for you we believe. Please bear in mind that if Millie does not respond well to this treatment then there is the likelihood that she may not be a suitable ridden horse in the medium to long term.

In the longer term we need to look at the weakened bone here, which is potentially going to be prone to fractures. There is a risk that this could happen at any stage, even just in the paddock. In order to try and improve the strength of the bone here, I would suggest a good Calcium supplement. We discussed your grass calcium levels, and I realise that with her 'HYPP' condition we need to be careful with her electrolytes, but a good organic calcium supplement should be ok as it should not affect her sodium/potassium metabolism too much. We sell one called PMC which is $195 for a month's supply, and is easily the best on the market which is why we ship it in from Europe.

Tildren is another product which could be used, and although I am sceptical of its use as a systemic treatment (and it costs over $1000!!) I do think it is helpful when used as a localised treatment just on the affected limb. This costs around $250-300 a treatment also, and if you are interested in this please let me know as I can explain the protocol and reasoning behind it in more detail.

There are some alternative treatments we could use such as Shockwave therapy, to try and get the body to start healing and working on the soft tissue damage in the hock area again. Ideally this is not done at the same time as the joint injections, as it works to increase blood supply whereas the injections are doing the opposite as they are anti-inflammatory. They are ok if given a week apart though. I have attached some information regarding this.

Arrow shows calcification of soft tissue within the tarsal sheath of the Right Hock. Area within the diamond shows weakened 'moth eaten' bone.

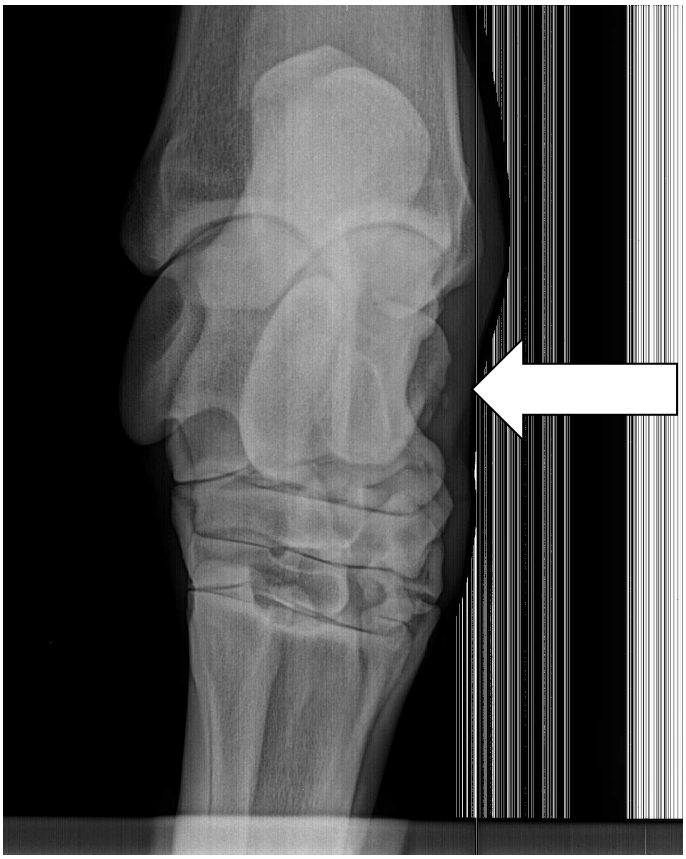

Arrow points to irregular area on the Talus at the back of the joint and some bone chips here. Compare to normal L Hock below which is smooth.

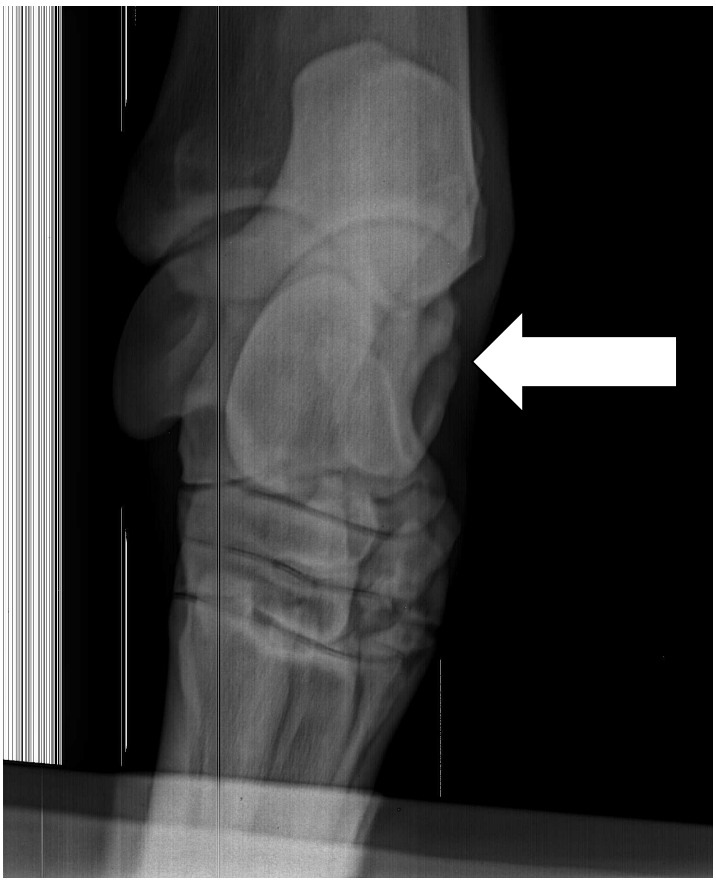

I hope I have explained the options to you (sorry if I have made it all muddled!!) Have a read and get back to me with any questions.

Thank you

Dr Fiona Jacob MA VetMB MRCVS